


Daniel P. Keenan, DVM

Lynsey D. Makkreel, DVM

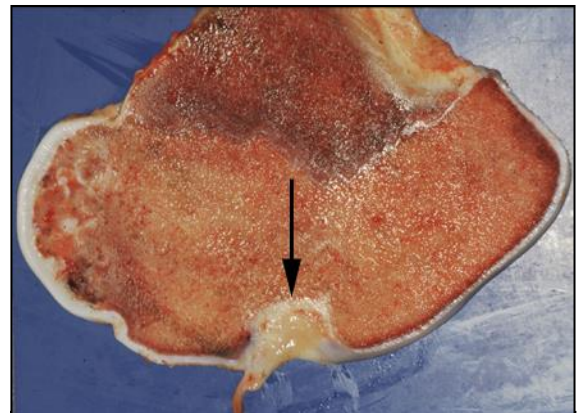
Talia M.A. Lin, DVM



## OSTEOCHONDROSIS (OCD)

### ***What is OCD?***

Osteochondrosis (OCD) is a failure of the bone underlying the smooth articular cartilage inside the joints to form properly from the skeleton's cartilage template. This weakness results in cracking and fissure formation in the articular cartilage, when the foal, yearling or young horse takes weight on its joints during exercise. Flaps and fragments of cartilage consequently form within the joint, some of which are transformed from cartilage into bone and are termed 'joint mice'. Osteochondrosis with free fragment formation is sometimes called Osteochondrosis dissecans. Chemicals that cause joint inflammation (synovitis) are released during the development of the flaps and fragments, or as a consequence of exercise on the abnormal surfaces. The affected joints may become visibly enlarged and distended with fluid and the horse may become lame, but there is no doubt that many cases never show symptoms of abnormality, are never recognized and resolve in time of their own accord.



**Post mortem specimen of bone cut to show area of OCD**

### ***What causes OCD?***

OCD is part of a group of conditions that occur in rapidly growing, young otherwise healthy horses collectively called developmental orthopedic disease (DOD). These conditions include acquired limb deviations (angular and flexural deformities), inflammation of the growth plates of bone (physitis), the development of bone cysts beneath the cartilage of joints and wobbler syndrome, which affects the neck vertebrae and causes in coordination.

There are many suggested causes of DOD and therefore OCD. Nutrition is of prime significance; this may be in the form of mineral deficiencies (copper, selenium), excesses (zinc, manganese) or imbalances (calcium, phosphorus). Excessively high energy and protein diets can predispose to very high growth rates in foals and yearlings resulting in defective subchondral bone development. For the same reason, a growth spurt that occurs following an episode such as illness or weaning can induce OCD.

---

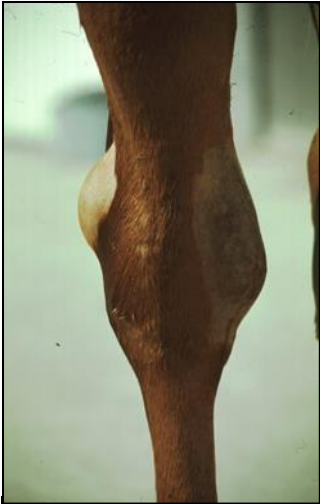Daniel P. Keenan, DVM      Lynsey D. Makkreel, DVM      Talia M.A. Lin, DVM

183B Bordentown Crosswicks Rd, Crosswicks, NJ 08515

Ph: 609-291-0535 Fax: 609-291-8899

[www.foundationequinenj.com](http://www.foundationequinenj.com)      info@foundationequinenj.com

Hormonal imbalances, involving insulin, thyroxin and growth hormone, may occur when growth rates are excessively encouraged, and these may result in improper subchondral bone development and cartilage maturation. There is evidence to suggest that there is a genetic or inheritable basis to OCD, or at least to its predisposition. Traumatic damage to the cartilage within joints may also occur particularly due to excessive exercise or conversely following prolonged stall rest, contributing to the development of OCD.



**Distended hock joint  
(bog spavin) from  
OCD**

### ***Which joints can be involved?***

Virtually any joint in the horse's skeletal system can develop OCD. The more commonly recognized joints include the hock, stifle, fetlock and between the neck vertebrae. The less common joints include the shoulder, elbow and hip. Often if a joint in one leg is involved, the same joint on the opposite leg also suffers from some degree of OCD.

### ***What are the symptoms?***

Often OCD does not cause recognizable symptoms and may be found coincidentally on radiographic examinations (x-ray pictures). However, the more typical presentation is seen in young horses (weanlings or yearlings) that have rapidly grown and are increasing their exercise levels. There may or may not be lameness with a swollen, fluid filled joint (synovial effusion). Following flexion of the joint the lameness may be exacerbated and palpation of the joint may cause pain.

### ***How is OCD diagnosed?***

Diagnosis is made on the basis of detailed radiographic examination of the suspected joints, sometimes performing a nuclear bone scan (scintigraphy) or by looking inside the joint with arthroscopic surgery to find the typical signs of abnormal bone shape, bone cysts, flaps, chips or fragments.

### ***What treatment options are there?***

There are two main approaches to the treatment of OCD. Conservative management includes a course of injections of polysulphated glycosaminoglycans or hyaluronic acid either intramuscularly or into the affected joint, to reduce the inflammation within the joint. This is in combination with stall rest, adjustment of the diet to reduce protein and energy intake and then supplement vitamins, minerals and trace elements and the inclusion of glucosamine in the diet.

The second option includes arthroscopic surgery to remove cartilage and bone fragments from the joint, trimming of frayed articular cartilage and flushing out the chemicals that cause inflammation from the joint. The measures used for conservative management are also employed following surgery.

The choice of which option to take depends upon the nature of the abnormality, the requirements for the horse and experience of previous similar cases.

---

Daniel P. Keenan, DVM      Lynsey D. Makkreel, DVM      Talia M.A.Lin, DVM

183B Bordentown Crosswicks Rd, Crosswicks, NJ 08515

Ph: 609-291-0535 Fax: 609-291-8899

[www.foundationequinenj.com](http://www.foundationequinenj.com)    info@foundationequinenj.com

### ***What is the outcome if OCD is left untreated?***

There is no doubt that many cases of mild OCD are never recognized and resolve naturally with time. However, in more significant cases, the swelling that occurs within the joint is due to the release of chemicals from the damaged cartilage and bone, which cause inflammation. These chemicals also contribute to the development of osteoarthritis or degenerative joint disease (DJD) which can result in chronic and permanent joint damage, so where symptoms are recognized these should be investigated by your veterinary surgeon. The first thing to do is to restrict the horse to stall rest pending results of investigations and careful consideration of the best options for your horse.

If OCD is detected in young foals the condition may be self-limiting and may resolve without surgical treatment. The foal should be periodically monitored both clinically (for joint swelling and lameness) and with follow-up radiographic examinations. There is also the possibility that further OCD lesions may develop in the same or in other joints so, in most cases in foals, surgery should be delayed until they are yearlings to avoid the necessity for repeated surgery. If OCD is first detected at yearling stage, the need for surgery is more likely.

### ***What is the prognosis for OCD following treatment?***

This is dependent on the number of joints involved, the site within the particular joint (weight bearing surface or not), the size of the lesion in the articular cartilage and the damage to the joint in-terms of osteoarthritis. The outcome may be excellent or poor, completely depending on individual circumstances.

### ***How can OCD be prevented?***

The provision of a correctly balanced diet (not only to the weanling and yearling but also and perhaps more importantly to the pregnant and lactating mare) containing the appropriate levels of vitamins, minerals and trace elements is helpful for the prevention of OCD. Several reputable feed companies offer diets and supplements specifically designed and formulated for horses of all ages and stages of their lives.

It is important to get exercise levels right. For normal foals, weanlings and yearlings, regular but not excessive exercise is essential to encourage normal musculoskeletal growth and development. There is evidence to suggest that exercise can also be protective against OCD. However, where OCD develops, exercise on the abnormal and inflamed joint can cause complicating damage (DJD) and so stall rest should be given as soon as OCD is suspected or diagnosed.

It is important to discourage rapid growth rates. Regular measurement of weight, girth and height can be used to assess growth rate. In order to reduce growth rate, some foals may need to be weaned earlier than usual. 'Growth spurts' can occur following weaning, when the foal is unaccustomed to eating creep feed. When this happens the foal's condition drops off and has to be made up once eating hard feed. This can be avoided by making sure the foal is eating hard feed prior to weaning so that there is a smooth transition. Avoid trying to force foals and yearlings to grow rapidly, particularly those that have lost condition due to illness. Foals and yearlings should be regularly examined for correctness of limb development and lameness in order that OCD can be detected and dealt with as early as possible.

---

Daniel P. Keenan, DVM      Lynsey D. Makkreel, DVM      Talia M.A.Lin, DVM

183B Bordentown Crosswicks Rd, Crosswicks, NJ 08515

Ph: 609-291-0535 Fax: 609-291-8899

[www.foundationequinenj.com](http://www.foundationequinenj.com)    info@foundationequinenj.com