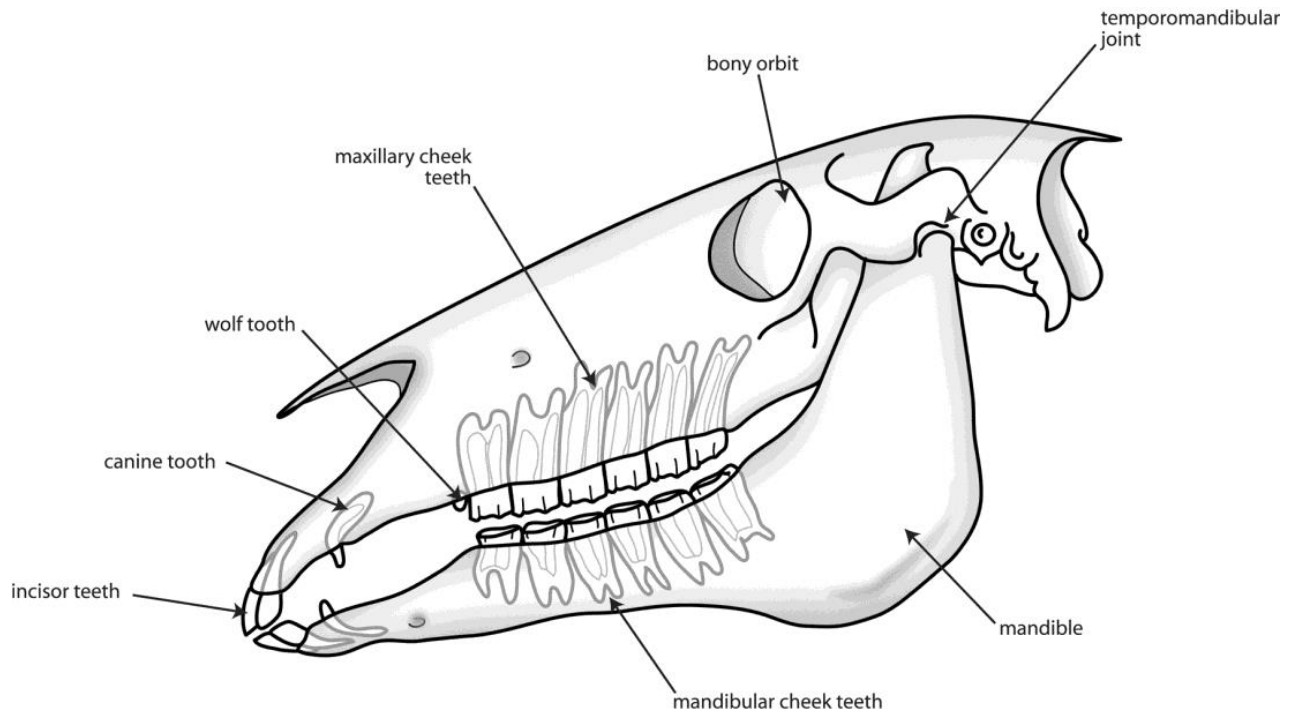


## EQUINE DENTISTRY

Horses and ponies are efficient herbivores. This is possible because they have evolved a set of specialized, slowly-wearing teeth.



The Equine Skull

## ***What sort of teeth do horses have?***

Horses have hypsodont teeth, meaning they gradually erupt and wear down over the course of a horse's life. However, unlike rabbits, horses have a finite amount of tooth. These teeth can be broken down into the following classes of teeth:

**Incisors:** Horses have 6 upper and 6 lower incisor teeth. These are simple in structure, deep-rooted and used to grasp and tear herbage, though horses can eat without them using their lips.

**Canines:** Canine teeth are the short and often sharp teeth found in the gap between the incisor teeth and cheek teeth on both the upper and lower sides of the mouth. Although generally only found in male horses, small canine teeth can also be found in some mares. Canine teeth erupt at around 4-5 years of age. The original purpose of canine teeth was as fighting weaponry and as such they serve no useful function in the modern horse.

**Wolf teeth:** Wolf teeth are small (often tiny) teeth that can be found immediately in front of the first upper cheek teeth. They erupt at 6-18 months and vary considerably in size and position. They can also rarely be found in front of the first lower cheek teeth. Not all horses have wolf teeth and, of those that do, the wolf teeth may not be fully erupted on both sides. Wolf teeth can be considered as an evolutionary dead-end, having once been 'molarized' teeth and serve no useful purpose in the modern horse. They are removed before bit training begins to prevent pain caused by pressure on their inadequate roots.

**Cheek teeth:** Horses have evolved dentition that allows them to spend a large part of their lives grazing on abrasive grasses. The cheek teeth do all the work grinding these grasses to prepare them for digestion. Horses have a total of 12 premolar and 12 molar teeth divided into an upper and lower row each of 6 cheek teeth on both the left and right sides of the mouth. While the premolar teeth have a deciduous (or baby tooth) precursor, which is ultimately shed as a cap, essentially adult premolar and molar teeth have the same appearance and function. Although both of the cheek teeth arcades are composed of 6 individual teeth, these teeth are tightly packed together and essentially act as a single grinding unit. The cheek teeth of young horses have a large amount of reserve crown below the gumline and for the majority of the horse's life these teeth will erupt into the mouth to make up for the wearing down of the grinding surface of the tooth. In old age, this constant eruption eventually results in some teeth wearing completely out. Cheek teeth are a composite of three hard materials: enamel, dentin and cementum, which complement each other to provide a uniquely abrasive surface ideal for breaking up food material.

### ***What is mastication?***

Mastication is the process of chewing food. In the horse, food is grasped by the incisor teeth or lips and moved back to the cheek teeth arcades by the combined action of the tongue and cheek muscles. The chewing motion of the mouth is controlled by several large muscles that act to slide the upper and lower cheek teeth against each other, breaking up the bolus of food before it can be swallowed.

### ***Why do horses need routine dental care?***

Horses have survived perfectly well for a long time without human intervention so it is sensible to question why it is necessary to perform equine dentistry at all. The answer lies not so much with the horse but with the circumstances in which it now exists. As we have discussed above, horse dentition is superbly adapted for a life of grazing on tough grasses for up to fourteen hours a day. Domestication has brought with it altered feeding patterns and many horses now spend little time grazing due to the feeding of energy-dense concentrates. Not only is less time spent chewing but it has also been shown that the type of feed given to the horse can alter its chewing pattern. The same features that make the cheek teeth ideal for a life of free-range grazing (such as continual eruption and abrasive grinding surface) can produce problems in the domesticated animal. The cheek teeth of the upper jaw are set wider than those of the lower jaw and with the altered pattern of chewing, sharp points can develop on the outer edges of the upper cheek teeth and the inner edges of the lower cheek teeth. These can rub and catch against the cheeks and tongue, causing ulcers.



In addition to the effects of an altered diet on the domesticated horse, horses are often asked to carry a bit, ride in collection and be responsive to cues. It is not hard to understand why oral comfort can prove to be so important. Horses these days are also living much longer than they might have done in their natural state. It is not uncommon for horses to outlive some of their teeth and routine dentistry in older horses and ponies focuses on preserving good function for as long as possible.

Finally, horses may develop abnormalities, such as cracked or rotten teeth that may be painful and result in abnormal chewing patterns. These problems can be detected during routine dentistry and corrected before they begin to cause weight loss and performance problems.

### ***What does routine dental floating involve?***

The process of removing potentially harmful sharp points and edges from the cheek teeth is called floating. This is done on a regular basis, usually annually. Before floating the teeth, a thorough examination of the mouth is performed. This is done using a device called a speculum, which keeps the mouth open. The veterinarian looks and feels inside the horse's mouth to check, not only for sharp points, but also for other problems such as broken or missing teeth, misalignment and signs of periodontal disease. Once the mouth has been examined, the teeth will be floated. Light sedation is used to facilitate the examination and floating. If part of the procedure is painful, nerve blocks to numb an area may be used. There are many different types of dental tools available and the practitioner has a range of instruments to allow work to be performed on teeth in various parts of the mouth.

### ***How often should routine dentistry be carried out?***

Although it is sensible for foals' teeth to be checked at a young age to pick up any developmental abnormalities, often the first thorough dental examination and floating occurs at 18 months to 2 years of age. Young horses can have surprisingly sharp teeth and it is wise to make the mouth comfortable prior to training. The frequency of dental examinations varies according to individual needs, but as a general rule of thumb, more frequent examinations are necessary in younger animals. Horses will shed 12 cheek teeth caps and 12 incisor caps and erupt 36 or more permanent teeth before the age of 5. This flurry of activity frequently means that there are sharp or loose teeth in the young mouth and examinations every 6 months are commonplace.

Once horses have obtained a mature mouth, annual visits often are sufficient to keep the mouth comfortable and balanced. However, some horses need more frequent care, particularly if there are any abnormalities of growth such as overlong or displaced teeth. When horses reach old age it is very important not to be too aggressive when rasping in order to preserve what grinding surface area remains in the mouth. For this reason, management of old horses may simply involve checking for loose or obviously diseased teeth, or may be more complicated as teeth that lose their opposing partner overgrow and make it difficult to chew.

### ***What should I do about my horse's wolf teeth?***

Wolf teeth are small teeth that sit immediately in front of the first upper cheek teeth and, rarely, the first lower cheek teeth. They come in many shapes and sizes and are usually present by 12-18 months of age, although not all horses have them. Most of the time wolf teeth do not cause problems, but traditionally owners and riders have considered them to be a potential cause of biting problems. This is because wolf teeth can sometimes be sharp or mal-erupted, wolf tooth might pinch the cheek with bit pressure or the shallow root on a wolf tooth can be insufficient to withstand the pressure of a bit. Sometimes the presence of wolf teeth can impair the thorough floating of the first cheek tooth.

Removal of wolf teeth can be simple or difficult but should always be done by a veterinarian who is comfortable administering local nerve blocks.

### ***How accurately can the age of horses and ponies be determined by examining their teeth?***

In the past it has been common to age horses by the appearance of their incisor teeth. The eruption and appearance of various features of these teeth have been associated with particular ages. However, it is now known that the technique is inherently inaccurate. A reasonable degree of accuracy exists up until the age of around 10 years, if the horse does not crib and has no other oral injuries. However, after that, it is best to talk in age groups of 5 or so years.

### ***What about 'caps'?***

'Caps' typically refer to the thin remnants of the deciduous (baby) cheek teeth. Horses will lose a total of 12 cheek teeth caps and 12 incisor caps generally between the ages of 2.5 and 4.5 years of age. Most of the time these are shed perfectly naturally, however, occasionally a young horse will salivate or show signs of mouth pain due to a partially dislodged or loose cap. Removal of these is simple and readily undertaken at a routine dental examination. Premature removal of caps is not advisable as it can damage the underlying adult tooth.

### ***What advanced dentistry is now practiced for horses and ponies?***

For the most part horses get through life with regular routine floating. There are occasions however when problems may arise:

**Developmental abnormalities:** Some horses develop teeth that, for one reason or another, erupt abnormally. The most common of these is the overbite, or 'parrot-mouthed' horse. Horses can also have an underbite (sow mouth) or poorly formed jaws (wry mouth). While

incisor problems rarely cause the horse discomfort, the same horses often have a misalignment of the cheek teeth arcades. Because the cheek teeth are designed to wear against each other, any unopposed tooth or part of a tooth can quickly become overgrown. In some cases large 'hooks' can develop at the front of the mouth or ramps at the back. Horses can have an uneven number of teeth (due to a missing tooth or extra tooth) and, if left untreated, the resulting overgrowth can cause oral discomfort and impede chewing.

**Fractured teeth:** Fractured cheek teeth are fairly common finding in horses' mouths. Sometimes the cause of these fractures can never be determined but in a large number of cases it is the result of the normal forces of chewing acting upon a tooth already weakened by disease. Fractured teeth do not cause problems in all cases; however, on occasion, they can result in painful chewing and even infection and death of the entire tooth. When this occurs, the tooth must be extracted to allow the horse to return to normal dental function.

**Cheek tooth infection:** If a horse develops a swelling on the face or jaw or a sinusitis (sinus infection) the underlying cause may be an infection of one of the cheek teeth. Infected cheek teeth often require removal either by standing surgery or under general anaesthesia. Evaluation and treatment of dental infections can be a complicated business and often require radiographic, endoscopic, and surgical procedures.

**Periodontal disease and diastema:** The cheek teeth of most horses erupt as a tight unit, effectively acting as a single tooth in each arcade. However, some horses have gaps between some of the teeth, either due to the loss of a tooth or to poor eruption. Food may become trapped in these gaps (diastemas), resulting in infection, gum disease and sometimes even tooth loss. Affected horses may suffer pain, difficulty chewing, and weight loss. Management is often problematic and ongoing treatment is usually necessary.