

SIDEBONES

What are sidebones?

Sidebones are a name for a condition which results in ossification of the collateral cartilages of the foot, that is, the cartilages transform into much harder and less flexible bone.

The collateral cartilages are found on the medial (inside) and lateral (outside) aspects of the foot and can be felt just above the level of the coronary band as flexible projections on each side of the pastern. They are normally important as shock-absorbers for the foot. Because cartilages are normally elastic, they allow the foot to deform during weight bearing, and then return to its previous shape.

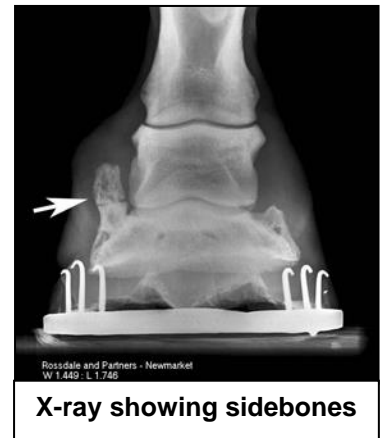
Sidebones develop more commonly in the front rather than the hind feet and are more frequently seen in the heavy (draft) breeds of horses than the lighter breeds and ponies.

Infection of sidebones is called quittor and is an uncommon condition usually occurring only in draft horses.

What causes sidebones to develop?

Ossification, starting at the junction of the collateral cartilages with the pedal bone (P3 or distal phalanx) is believed to be part of most horse's normal ageing processes. Mild sidebone formation, not associated with lameness, is not uncommonly seen in radiographs taken from older horses and young heavy working horses. Excessive, abnormal or premature sidebone formation may result from undue loading and concussion of the cartilages, which may be predisposed by a number of things:

- Poor foot conformation, especially chronic imbalance, associated with incorrect
- hoof trimming and/or shoeing.
- Foot lameness from whatever cause, particularly if this is due to chronic imbalance.
- Abnormal limb conformation may cause uneven forces on the collateral cartilages.
- Direct trauma to the collateral cartilages may also precipitate sidebone formation.



How are sidebones diagnosed?

Sidebones may be palpable above the coronet, when there is loss of normal pliability of the heel over the cartilage. The coronary band may bulge over the affected cartilage and the adjacent hoof wall may become more upright in conformation.

Lameness, primarily associated with sidebones, is rarely seen and if lameness occurs it is usually caused by complicating features, such as when the ossification becomes advanced and the growing sidebones press on adjacent sensitive hoof structures and deform the foot.

Ossification of the cartilages is confirmed by radiographic examination of the foot (normal cartilage cannot be seen, whereas bony ones can), comparing one foot with another to aid interpretation.

How can sidebones be treated?

Uncomplicated, normal, progressive ossification of the sound horse's collateral cartilages causes no clinical problems and requires no treatment. Where clinical problems occur, most importantly lameness, it is most important to identify and treat the complicating or predisposing problems.

Foot imbalance should be corrected by skilled trimming and shoeing

Fit a flat, wide-webbed shoe, with a rolled toe, wide at the quarters and heels and extending beyond the ground surface at the heels, to support the heel and encourage expansion. No nails should be used behind the mid-quarters.

The horse should have an extended period of rest (6-8 weeks).

Your veterinarian may recommend a course of non-steroidal anti-inflammatory medication if the condition is causing lameness.

The affected foot should be re-shod regularly to gradually encourage heel expansion.



Searching a foot for signs of abnormality

How can sidebones be prevented?

Your horse's feet should be regularly trimmed and shod to prevent imbalance, uneven weight-bearing and to ameliorate concussive forces in the foot.

Caution

The prognosis for complete resolution and return to soundness is poor for cases where sidebones are causing lameness, especially those with extensive cartilage ossification and hoof deformity.

So called 'fractured' sidebones, sometimes seen at radiographic examinations, are usually separate centers of ossification (bone formation), and do not indicate a problem.

If your horse is lame, all other causes should be excluded before sidebones are incriminated.